

Original Investigation

Epidemiologic, Clinicopathologic, Diagnostic, and Management Challenges of Pityriasis Rubra Pilaris

A Case Series of 100 Patients

Nicholas A. Ross, MD; Hye-Jin Chung, MD; Qiaoli Li, PhD; Jonathan P. Andrews, MD; Matthew S. Keller, MD; Jouni Uitto, MD, PhD

IMPORTANCE Pityriasis rubra pilaris (PRP) is a rare papulosquamous disorder with limited epidemiologic and clinicopathologic data. Little information is available on long-term outcomes, comorbidities, and treatment efficacy.

OBJECTIVE To evaluate objective and subjective disease experience metrics from the perspectives of patients and clinicians.


DESIGN, SETTING, AND PARTICIPANTS One hundred patients with a putative diagnosis of PRP and who elected to participate completed a comprehensive survey, followed by acquisition of their medical records, including histopathology slides and reports. The data were analyzed separately from the health care clinician and the patient perspectives. Two academic dermatologists examined clinical notes, pathology reports, and photographs, confirming diagnoses via predetermined criteria. Patients were categorized into 4 levels of diagnostic certainty to allow stratification of the findings for subgroup analysis. Patients with a diagnosis of PRP were solicited through patient support organization websites.

MAIN OUTCOMES AND MEASURES Clinical outcomes, unexpected association of comorbidities, and efficacy (or lack of it) of various treatment modalities.

RESULTS Among the 100 patients, 50 were diagnosed as having classic, unquestionable PRP. The patients were a median of 61 years old (range, 5-87 years), and 46% were female. Fifty were categorized as level 1 diagnostic certainty, 15 as level 2, 30 as level 3, and 5 as level 4. Of the level 1 patients, 13 (26%) were correctly diagnosed at initial presentation; diagnosis was delayed, on average, by 29 months (range, 0.25-288 months; median, 2 months); and 27 (54%) having undergone 2 or more biopsies. At enrollment, PRP symptoms had persisted in 36 patients (72%) for an average of 58 months (range, 1-300 months; median, 30 months). Thirty-one patients (62%) had comorbidities, including hypothyroidism (20%). Nearly all patients (98%) received some form of therapy. Patients cited topical emollients, corticosteroids, and salicylic acid along with oral retinoids, methotrexate, and tumor necrosis factor inhibitors as most helpful.

CONCLUSIONS AND RELEVANCE Pityriasis rubra pilaris remains a challenging diagnosis without established and specific treatment. Our data highlight new potential avenues for research with therapeutic perspective.

JAMA Dermatol. doi:10.1001/jamadermatol.2016.0091
Published online March 9, 2016.

 Supplemental content at jamadermatology.com

Author Affiliations: Department of Dermatology and Cutaneous Biology, Thomas Jefferson University, Philadelphia, Pennsylvania (Ross, Chung, Li, Andrews, Keller, Uitto); Department of Dermatology, Dermatopathology Section, Boston University School of Medicine, Boston, Massachusetts (Chung).

Corresponding Author: Jouni Uitto, MD, PhD, Department of Dermatology and Cutaneous Biology, The Sidney Kimmel Medical College at Thomas Jefferson University, 233 S 10th St, Ste 450 BLSB, Philadelphia, PA 19107 (Jouni.Uitto@jefferson.edu).

Pityriasis rubra pilaris (PRP) is an inflammatory papulosquamous skin disorder first reported by Tarral in 1835¹ and later fully characterized by Devergie in 1856.² The clinical features of classic PRP affecting the skin and nails are detailed elsewhere.³⁻⁵ Histopathologic findings reveal psoriasiform dermatitis with irregular hyperkeratosis and alternating vertical and horizontal orthokeratosis and parakeratosis, referred to as the “checkerboard pattern.”⁶ Acantholysis and focal acantholytic dyskeratosis within the epidermis have been described, features which have been suggested to be helpful in distinguishing PRP from psoriasis.⁷

Based on the age at onset, the disease course, and associated underlying conditions, Griffiths⁸ categorized PRP into 5 types: type 1: classic adult type; type 2: atypical adult type; type 3: classic juvenile type; type 4: circumscribed juvenile type; and type 5: atypical juvenile type. More recently, human immunodeficiency virus-associated PRP was categorized as a separate type (type 6).⁹

Pityriasis rubra pilaris is considered a rare disease, with an estimated incidence of 1 in 400 000, yet the precise prevalence is unknown.⁸ Because of its low prevalence, relatively little has been reported about epidemiologic trends, clinicopathologic features, and disease course. This multinational study of 100 patients seeks to describe epidemiologic, clinicopathologic, diagnostic, and therapeutic features, as well as patient impressions, of adult and pediatric PRP.

Methods

Study Design and Patient Recruitment

Prospective patients were recruited through 2 PRP support group websites (<http://www.prp-support.org/wp/> and <http://prpalliance.com>). Patients requesting enrollment received, and completed, a Thomas Jefferson University institutional review board-approved informed consent form, together with a release of medical records forms, and the survey tool. Patients were not compensated for their participation.

Study Procedures

The patient survey consisted of 7 sections: (1) diagnosing and/or identifying information on treating physician(s), (2) demographic data, (3) description of symptoms and signs, (4) diagnostic procedures, (5) treatments, (6) medical history, and (7) disease course. Regarding treatments, patients were queried about the utility and perceived helpfulness of each modality. Using the informed consent and authorization to release medical records, study personnel obtained original clinical notes, pathology reports, and photographs.

The first 100 patients requesting enrollment, who self-identified as having a diagnosis of PRP, were included in the study. Two study dermatologists (H.J.C. and M.S.K.) systematically reviewed each patient’s medical record, independently, using predetermined criteria to assess the level of diagnostic certainty (Table 1).

Key Points

Question: What is the typical presentation and outcome of pityriasis rubra pilaris (PRP)?

Findings: In this case series study of 100 patients with PRP, we found that only a quarter of patients were correctly diagnosed at initial presentation, and most patients required more than 2 biopsies before a final diagnosis was made. Patients rated topical emollients, corticosteroids, and salicylic acid along with oral retinoids, methotrexate, and tumor necrosis factor inhibitors as most helpful.

Meaning: Pityriasis rubra pilaris remains a challenging diagnosis.

Table 1. Preset Criteria Used in This Study for Assessment of the Level of Diagnostic Certainty of Patients With the Diagnosis of Pityriasis Rubra Pilaris (PRP)

Level of Diagnostic Certainty	Definition ^a	Patients, No. ^b
1	Patients with unquestionable clinical, histopathologic, or photographic evidence, or combination thereof, “consistent with,” “in keeping with,” or “confirmatory of,” PRP. Typical clinical presentations included follicular hyperkeratosis, salmon-colored to orange-red plaques with distinctive “islands of sparing,” prominent erythema on the extensor surfaces of the elbows and knees, palmar-plantar hyperkeratosis, erythrodermic appearance with varying degrees of exfoliation and erythema with a fine diffuse scale on the scalp. Histopathologic findings revealed psoriasiform hyperplasia with irregular hyperkeratosis and alternating vertical and horizontal orthokeratosis and parakeratosis. Presence of spongiosis, acantholysis, and/or focal acantholytic dyskeratosis were helpful in distinguishing PRP from psoriasis but were not sine qua non.	50
2	Patients with clinical, histopathologic, or photographic evidence suggestive of PRP but having neither all the classic features of PRP nor findings that were more suggestive of another disease as a more likely diagnosis.	15
3	A mixed group of patients with findings that may, in fact, be those of PRP, although there were insufficient data to confirm the diagnosis of PRP or rule it out. A mixture of histopathologic features, including specific (checkerboard alternating orthokeratosis and parakeratosis) and nonspecific (hyperkeratosis, parakeratosis, psoriasiform hyperplasia) provided evidence for the diagnosis of PRP, but the histopathologic differential diagnosis remained suggestive of alternative diagnoses.	30
4	Patients enrolled with a self-reported diagnosis of PRP but having clinical, histopathologic, or photographic evidence favoring an alternative diagnosis. These patients lacked the classic clinical features of PRP and histopathologic features seen on biopsy specimens that were nonspecific with a constellation of findings more consistent with an alternative diagnosis.	5

^a For further details and histopathologic correlations regarding each category, see the Supplement.

^b Number of patients classified into each Level of Diagnostic Certainty among the 100 patients who entered the study with a putative diagnosis of PRP.

Questionable diagnoses were discussed jointly, applying these same criteria, until a consensus was reached. These levels of diagnostic certainty, from 1 to 4, enabled subgroup data analysis, thus minimizing confounding bias.

Results

Epidemiologic Characteristics of the Cohort

Of the 100 enrolled patients with the putative diagnosis of PRP, 50 were categorized as level 1; 15 as level 2; 30 as level 3; and 5 as level 4, respectively.

At the time of enrollment, patients of this cohort of 100 were a mean age of 57 years (range, 5-87 years; median, 61 years); 46% were female. The self-identified ethnic distribution was 93% white, 4% black, 1% Arabic, and 1% Hebrew. Twelve countries (United States, Canada, The Netherlands, Germany, France, Sweden, Denmark, Switzerland, United Kingdom, Dubai, Australia, and New Zealand) were represented in the cohort. The demographics are summarized in eTable 1 in the Supplement.

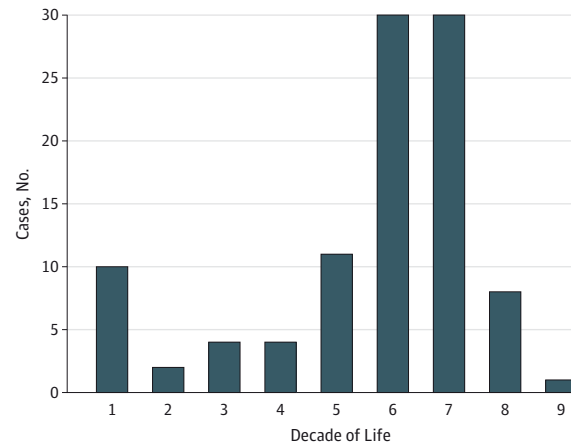
Level 1 patients were an average of 59 years of age (range, 5-84 years; median, 65 years) at enrollment. This subgroup was 56% female. The average age at symptom onset in level 1 adult cases (>19 years of age) was 57 years (range, 25 to 80 years; median, 60 years). In pediatric cases (≤ 19 years of age) the onset was at 7 years of age (range, 2-13 years; median, 4 years). Bimodal peaks in the age at the onset of symptoms were noted in the entire study cohort during the first and second (12% of cases) and again in the sixth and seventh decades (60%) of life (Figure). Similar distribution was also observed in the level 1 patients (6% and 52%, respectively).

Diagnostic Features

Only 13 level 1 patients (26%) reported being correctly diagnosed as having PRP on initial presentation. The next most common initial diagnoses reported were psoriasis, contact dermatitis, and eczema and/or spongiotic dermatitis, which accounted for 42% of level 1 initial diagnoses (Table 2). The mean time to obtain the correct diagnosis was 29 months from the initial presentation (range, 0.25-288 months; median, 2 months). Twenty-seven patients (54%) reported undergoing 2 or more biopsies (mean, 2; range, 0-7 biopsies) to establish the diagnosis of PRP. The mean age at the time of diagnosis in level 1 adult cases was 58 years (range, 29-80 years; median, 60 years). In pediatric cases it was 16 years (range, 2-37 years; median, 4 years).

The spectrum of signs and symptoms in level 1 patients was broad. Forty-five patients (90%) reported widespread erythematous plaques, 10 (20%) reported prominent erythema on the extensor surfaces of the elbows and knees, and 14 (28%) reported associated hyperkeratosis, skin thickening, or tightening. Thirty-nine (78%) noted palmar-plantar hyperkeratosis, thickening, or tightening. Skin flaking or ichthyosis was reported by 45 patients (90%). The presence of perifollicular erythema and scales was reported by 38 individuals (76%). Alopecia was noted in 35 patients (70%). Twelve (24%) indicated associated eczematous changes. Nail involvement, ranging from thickening and discoloration to complete sloughing of the nails, was described by 36 patients (72%). Pruritus was noted by 40 patients (80%), yet a burning sensation of the skin was noted only by 25 patients (50%).

Figure. Age at Onset of Symptoms in Patients With Putative Pityriasis Rubra Pilaris, by Decades of Life



Note bimodal distribution with peaks in the first and the sixth to seventh decades.

Table 2. Initial Diagnoses of Patients as Documented by the Examining Physicians, by the Level of Diagnostic Certainty

Diagnosis	Patients, No. (%) ^a			
	Level 1 (n = 50)	Level 2 (n = 15)	Level 3 (n = 30)	Level 4 (n = 5)
Pityriasis rubra pilaris ^b	13 (26)	6 (40)	11 (37)	2 (40)
Psoriasis	12 (24)	3 (20)	0	1 (20)
Contact dermatitis, allergic and irritant	5 (10)	1 (7)	0	1 (20)
Eczema/spongiotic dermatitis	4 (8)	1 (7)	2 (7)	0
Seborrheic dermatitis	3 (6)	0	0	0
Drug eruption	2 (4)	0	1 (3)	0
Neurodermatitis	2 (4)	0	0	0
Pityriasis rosea	2 (4)	1 (7)	1 (3)	0
Psoriasiform dermatitis	1 (2)	0	1 (3)	0
Mycosis fungoides	1 (2)	0	0	0
Parapsoriasis	1 (2)	0	1 (3)	0
Lupus	1 (2)	1 (7)	0	0
Dermatitis, not otherwise specified	1 (2)	0	1 (3)	0
Tinea	1 (2)	0	0	0
None reported	5 (10)	2 (13)	13 (43)	2 (40)

^a Some patients indicated 1 or more initial diagnoses; as such, columns contain more diagnoses than the cohort size, and percentages sum to greater than 100%.

^b These patients received a diagnosis of pityriasis rubra pilaris at initial presentation.

In level 1 adult and pediatric patients, 32 (64%) and 4 (8%) indicated persistent, ongoing symptoms of PRP, at the time of the study, respectively. Thirteen of level 1 adult patients (26%) and 1 pediatric patient (2%) reported remission at the time of study enrollment (see eTable 1 in the Supplement). The former patients (adult plus pediatric) noted that their symptoms had been present for an average of 58 months (range, 1-300 months; median, 30 months). Twenty-four of these individuals (48%) indicated that they were diagnosed as having PRP type 1; 2 (4%) indicated type 2; 4 (8%), type 3; and none as types

Table 3. Comorbidities as Reported by the Patients With Pityriasis Rubra Pilaris (PRP), by the Level of Diagnostic Certainty

Comorbidity	Patients, No. (%)				
	Level 1 (n = 50)	Level 2 (n = 15)	Level 3 (n = 30)	Level 4 (n = 5)	Total (n = 100)
Cutaneous ^a	7 (14)	2 (13)	7 (23)	1 (20)	17 (17)
Myasthenia gravis	0	1 (7)	0	0	1 (1)
Celiac sprue	1 (2)	1 (7)	0	0	2 (2)
Myositis	1 (2)	1 (7)	0	0	2 (2)
Hypothyroidism	10 (20)	2 (13)	2 (7)	0	14 (14)
Malignancy	5 (10)	2 (13)	1 (3)	1 (20)	9 (9)
HIV	0	1 (7)	0	0	1 (1)
Dyslipidemia	9 (18)	5 (33)	5 (17)	1 (20)	20 (20)
Diabetes mellitus	4 (8)	1 (7)	0	1 (20)	6 (6)
Cardiovascular disease, HTN, CAD, HF, etc	1 (2)	5 (33)	1 (3)	0	7 (7)
Other	6 ^b (12)	5 ^c (33)	2 ^d (7)	0	13 (13)
No comorbidities	19 (38)	6 (40)	13 (43)	2 (40)	40 (40)

Abbreviations: CAD, coronary artery disease; HF, heart failure; HTN, hypertension.

^a Cutaneous conditions other than PRP.

^b Normal pressure hydrocephalus, sleep apnea, colon polyps, inflammatory bowel disease, spinal stenosis, thrombocytopenia, rheumatoid arthritis.

^c Cardiac conduction deficits, alopecia.

^d Peptic ulcer disease, sleep apnea, degenerative joint disease.

4 to 6. The remaining 20 patients (40%) did not indicate their type of PRP. Of the 14 patients in remission, the average length of their disease course had been 84 months (range, 4-516 months; median, 44 months). Only 1 of these was a pediatric case, with a 5-year disease course (diagnosed at 7 years of age). In the remaining 4 level 1 pediatric cases, symptoms had persisted, on average, 124 months (range, 12-348 months; median, 96 months). The symptoms in level 2 pediatric cases had persisted, on average, for 81 months (range, 15-156 months; median, 72 months), in level 3 pediatric cases, on average, 68 months (range, 36-120; median, 48), and in the level 4 pediatric case, 40 years.

Histopathologic Findings

Representative biopsies of 69 patients (69%) were obtained. Most level 1 patients (54%) reported having had 2 or more biopsies mean, 2; range, 0-7 biopsies). Characteristic epidermal features noted were acanthosis, hyperkeratosis, as well as orthokeratosis and parakeratosis in a “checkerboard pattern” (see eTable 2 in the Supplement).

The dermis most commonly showed alterations (eg, dilation) in vasculature with primarily perivascular, lymphohistiocytic infiltrates. In the study cohort of 100 patients, PRP was the most common clinical differential diagnosis on the histopathology referral forms available for review (n = 31); the next most common were psoriasis (n = 16), cutaneous T-cell lymphoma (n = 9), eczema (n = 6), and drug reaction (n = 4) (see eTable 3 in the Supplement).

Comorbidities

The available medical history revealed that 31 patients of level 1 of diagnostic certainty (62%) had 1 or more significant comorbidity; these are detailed in Table 3. The 3 most common disorders were hypothyroidism in 10 (20%), dyslipidemias in 9 (18%), and other cutaneous comorbidities in 7 (14%).

Thirteen (26%) patients indicated that they experienced depression “always” or “often”; 15 (30%) experienced symptoms “sometimes”; and 10 (20%) “rarely” (eTable 4 in the Supplement).

Only 6 (12%) indicated that they are “never” depressed. When asked what percentage of their depression they believe is secondary to PRP, nearly half (46%) said that it was primarily (51%-100%) related to their skin disorder.

Treatment History

Ninety-six patients of the total cohort of 100 (96%) indicated that they received either a topical or oral therapy during the course of their disease; 49 level 1 patients (98%) used some form of therapy (Table 4). The 3 most commonly reported topical therapies were emollients (90%), corticosteroids (76%), and urea (68%). Among these, emollients (76%), corticosteroids (50%), and salicylic acid (45%) were perceived most helpful by the patients.

The most commonly used systemic therapies were retinoids (64%), methotrexate (42%), and light therapy (26%). Systemic modalities rated as most helpful were retinoids (59%), methotrexate (52%), and tumor necrosis factor (TNF) inhibitors (40%). Interestingly, although light therapy was one of the most common systemic therapies used, only 1 in 13 patients found it helpful. Few patients were prescribed TNF inhibitors (20%), but these were considered most helpful by 4 of level 1 patients (40%), and of the 19 patients (across all levels of diagnostic certainty) who reported use of TNF inhibitors, 5 (26%) believed them to be helpful.

Discussion

This study presents epidemiologic, clinicopathologic as well as diagnostic and treatment challenges in 100 patients with a self-reported diagnosis of PRP. As such, to our knowledge, this is the largest reported cohort of patients with PRP. In addition, this is also the first study to provide patient perspectives regarding the diagnostic and treatment course of PRP. The evidence supporting the putative diagnosis of PRP was subsequently reviewed to subcategorize the patients to 4 levels of diagnostic certainty. As such, cases belonging to levels 1 to 3 represent a spectrum of phenotypes that dermatologists

Table 4. Topical and Systemic Treatments and Impressions of Their Helpfulness as Reported by Patients With PRP, by the Level of Diagnostic Certainty

Treatment	Patients, No. (%)							
	Level 1 (n = 50)	Helpful ^a	Level 2 (n = 15)	Helpful ^a	Level 3 (n = 30)	Helpful ^a	Level 4 (n = 5)	Helpful ^a
Topical therapy								
Emollients	45 (90)	34 (76)	12 (80)	8 (67)	23 (77)	9 (39)	3 (60)	1 (33)
Corticosteroids	38 (76)	19 (50)	13 (87)	5 (38)	22 (73)	3 (14)	3 (60)	1 (33)
Urea	34 (68)	11 (32)	5 (33)	4 (80)	7 (23)	3 (43)	3 (60)	1 (33)
Salicylic acid	11 (22)	5 (45)	3 (20)	1 (33)	3 (10)	2 (67)	2 (40)	1 (50)
Retinoids	9 (18)	4 (44)	5 (33)	4 (80)	4 (13)	0	0	0
Vitamin D derivatives	3 (6)	1 (33)	0	0	1 (3)	0	0	0
Calcineurin inhibitors	1 (2)	0	0	0	2 (7)	0	0	0
Systemic therapy								
Retinoids	32 (64)	19 (59)	6 (40)	4 (67)	9 (30)	4 (44)	3 (60)	1 (33)
Methotrexate	21 (42)	11 (52)	7 (47)	3 (43)	9 (30)	2 (22)	1 (20)	0
Light therapy	13 (26)	1 (8)	8 (53)	0	8 (27)	0	1 (20)	0
Tumor necrosis factor inhibitors	10 (20)	4 (40)	4 (27)	0	4 (13)	0	1 (20)	0
Other therapies ^b	3 (6)	NA	0	NA	0	NA	1 (20)	NA

Abbreviations: NA, not applicable; PRP, pityriasis rubra pilaris.

^a Subjective, patient-reported "helpfulness." Percentages were calculated as a fraction of those who had tried this therapy. Patients were asked as to whether the specific therapy listed was "helpful;" while most patients appeared to have understood the question as pertaining to the improvement of their signs and symptoms of PRP, survey notes indicated that certain patients considered their treatment "not helpful" because it was too time consuming, had too many adverse effects, and so on.

^b Other systemic therapies reported by the patients included cyclosporine, antidepressants for pruritus, antihistamines, antibiotics, acupuncture, cerumen softener, Restasis ophthalmic drops, and over-the-counter supplements (including neotigason, L-glutamine, β hydrochloride, lipase, dihydroepiandrosterone, cortisol manager, adrenal essence, vitamin A, zyflamend, vitamin D, vitamin E, fish oil). The questionnaire did not inquire whether these additional therapies were helpful.

around the world, to the best of their knowledge, are diagnosing and treating as PRP. Interestingly, although level 4 patients were deemed to have a diagnosis other than PRP, each one of these patients were, at one point, suspected of having PRP. This further demonstrates the diversity and variation in presentations over time and the diagnostic challenge that this entity poses.

The clinical features, forming the basis of the diagnosis of PRP, are varied but well described in the literature.^{3,5} Its highly variable clinical presentation indeed raises the question whether PRP is a single disorder or numerous disorders with a common final pathway. While the influences are likely varied, it seems that it is a single disorder with a multitude of factors leading to varied presentations that progress to a more uniform, final appearance of exfoliative erythroderma in most cases. We demonstrated 2 peaks of onset: one during the first decade of life and a second one in the sixth and seventh decades of life. This has similarities with previously reported peaks of onset of the disease.^{3,8,10} It also seems that the patients progress to "full bloom" (both clinically and histopathologically) at different rates, which results in variable timing required to obtain the correct diagnosis (eg, with repeated biopsies and clinical examinations). Further studies aimed at defining the exact timing of the disease progression would be useful to dermatologists to determine the return visit timing in cases with an inconclusive initial diagnosis; this may in turn reduce diagnostic delay and costs associated with this difficult diagnosis.

One of the most striking observations in this study was that only 26% of level 1 patients were correctly diagnosed at ini-

tial presentation. Diagnosis was delayed 29 months, on average, with a wide range. This delay may primarily reflect the fact that at early stages, presentation of cutaneous findings can be highly variable. Over time, these signs most often evolve into classic features of PRP, facilitating diagnosis. A similar trend was seen in histopathologic diagnosis: the broad array of findings necessitated numerous follow-up biopsies in most patients to enable establishment of the correct diagnosis. Many times, even findings from follow-up biopsies were inconclusive, necessitating clinicopathologic correlation.

Traditionally, PRP has been suggested to be a self-limiting condition, the symptoms subsiding within a 2- to 3-year time frame.⁸ However, at the time of our study, 72% of level 1 patients had persistent clinical findings, which had lasted for 58 months on average with a range up to 300 months. Only 28% of adult plus pediatric patients had entered remission before our study was completed; in these cases, the mean length of skin manifestations was 84 months (range, 4-516 months). These findings clearly suggest that PRP, while in some cases a readily self-limiting condition, can persist well beyond the anticipated 2- to 3-year course in other cases.¹¹ In fact, the natural history of this seems to be more variable than previously realized. This has obvious implications when counseling newly diagnosed patients.

Survey of the patients with PRP in our study revealed a number of comorbidities, some of which, such as dyslipidemia, may not differ from the frequency in general population. An increased incidence of hypothyroidism was found in level 1 patients with PRP (20%) vs the general US population (4.6%).¹² In this context, several case studies have previously

reported hypothyroidism in patients with PRP, and some studies have suggested disappearance of PRP on correction of the hypothyroid state.^{13,14} While the pathomechanistic link between thyroid function and cutaneous manifestations in PRP remain unclear, further study of this connection may provide potentially new therapeutic avenues.

Essentially, all of the entire cohort (96%), and 98% of level 1 patients, had been prescribed some form of oral or systemic therapy. The patients were queried in this study about their impressions of the helpfulness of specific treatment modalities. While most patients found topical treatment with emollients, corticosteroids, and urea to be helpful, it is not clear as to what extent they improved the disease signs and symptoms. Among the systemic therapies, level 1 patients with definitive PRP found systemic retinoids and methotrexate most helpful, and a limited number of patients, 10 who received treatment with TNF inhibitors (20%), found them helpful. Of note, patients were not asked specifically regarding

ustekinumab, although it shows promising use in familial PRP.¹⁵⁻¹⁹ Interestingly, among the 15 patients treated with light therapy, only 1 (8%) found it helpful. It should be noted that this study did not examine the length of systemic treatment or the dosages of the drugs used in detail; nevertheless, none of the topical or systemic treatments lead to uniform improvement in all patients with PRP. The difficulty in treating PRP is also reflected by the number of therapies patients had tried, as listed in Table 4.

Conclusions

Pityriasis rubra pilaris remains an extremely challenging disease to diagnose and treat. At the same time, search for biomarkers, such as genetic alterations linked to development and progression of PRP, would be helpful for diagnosis and prognostication in these challenging cases.²⁰

ARTICLE INFORMATION

Accepted for Publication: January 17, 2016.

Published Online: March 9, 2016.

doi:10.1001/jamadermatol.2016.0091.

Author Contributions: Drs Ross and Uitto had full access to all of the data in the study and take responsibility for the integrity of the data and the accuracy of the data analysis.

Study concept and design: Ross, Chung, Li, Keller, Uitto.

Acquisition, analysis, or interpretation of data: All authors.

Drafting of the manuscript: Ross, Uitto.

Critical revision of the manuscript for important intellectual content: All authors.

Statistical analysis: Ross, Keller.

Obtained funding: Ross, Uitto.

Administrative, technical, or material support: Ross, Chung, Li, Andrews, Uitto.

Study supervision: Ross, Chung, Li, Keller.

Conflict of Interest Disclosures: None reported.

Funding/Support: This study was supported in part by National Institutes of Health/National Institute of Arthritis and Musculoskeletal and Skin Diseases grant K01 ARO64766 (Q.L.), a research grant from the Dermatology Foundation (Q.L.), and a grant from Edwin Pratt Jr through the Cove Charitable Trust, Boston, Massachusetts (J.U.).

Role of the Funder/Sponsor: The funding sources had no role in the design and conduct of the study; collection, management, analysis, and interpretation of the data; preparation, review, or approval of the manuscript; and decision to submit the manuscript for publication.

Additional Contributions: We thank the patients for their participation as well as the web administrators of <http://www.prp-support.org/wp/> and <http://prpalliance.com>, Jeremy Bishop, MSc, and William McCue, BA, respectively, for their contributions to this research study. Richard

Greene, PhD, provided invaluable assistance. They were not compensated for their contributions.

REFERENCES

- Tarral C. Observation CXVIII. In: Rayer P, ed. *Traite theorique et pratique des maladies de la peau*. Vol 2. Paris, France: Bailliere; 1835:158-159.
- Devergie MGA. Pityriasis rubra pilaris, maladie de peau non decrite par les dermatologistes. *Gazette Hebdomadaire de Medicine et de Chirurgie*. 1856;31856:197-201.
- Wood GS, Reizner GT. Other papulosquamous disorders. In: Bologna JL, Jorizzo JL, Schaffer JV, eds. *Dermatology*. 3rd ed. Philadelphia, PA: Elsevier; 2012:157.
- Albert MR, Mackool BT. Pityriasis rubra pilaris. *Int J Dermatol*. 1999;38(1):1-11.
- Klein A, Landthaler M, Karrer S. Pityriasis rubra pilaris: a review of diagnosis and treatment. *Am J Clin Dermatol*. 2010;11(3):157-170.
- Soeprono FF. Histologic criteria for the diagnosis of pityriasis rubra pilaris. *Am J Dermatopathol*. 1986;8(4):277-283.
- Magro CM, Crowson AN. The clinical and histomorphological features of pityriasis rubra pilaris: a comparative analysis with psoriasis. *J Cutan Pathol*. 1997;24(7):416-424.
- Griffiths WA. Pityriasis rubra pilaris. *Clin Exp Dermatol*. 1980;5(1):105-112.
- Misery I, Faure M, Claidy A. Pityriasis rubra pilaris and human immunodeficiency virus infection: type 6 pityriasis rubra pilaris? *Br J Dermatol*. 1996;135(6):1008-1009.
- Marrouche N, Kurban M, Kibbi AG, Abbas O. Pityriasis rubra pilaris: clinicopathological study of 32 cases from Lebanon. *Int J Dermatol*. 2014;53(4):434-439.
- Abbott RA, Griffiths WA. Pityriasis rubra pilaris type 1 spontaneously resolving after 20 years. *Clin Exp Dermatol*. 2009;34(3):378-379.
- Hollowell JG, Staehling NW, Flanders WD, et al. Serum TSH, T(4), and thyroid antibodies in the United States population (1988 to 1994): National Health and Nutrition Examination Survey (NHANES III). *J Clin Endocrinol Metab*. 2002;87(2):489-499.
- Franzotti AM, Avelar JC, Cardoso TA, Pires MC, Vidigal MdoR. Pityriasis rubra pilar and hypothyroidism. *An Bras Dermatol*. 2014;89(3):497-500.
- Orlandini V, Cogrel O, Doutre MS, Beylot C, Beylot-Barry M. Pityriasis rubra pilaris and hypothyroidism. Efficacy of thyroid hormone replacement therapy in skin recovery. *Br J Dermatol*. 2007;156(3):606-607.
- Di Stefani A, Galluzzo M, Talamonti M, Chiricizzo A, Costanzo A, Chimenti S. Long-term ustekinumab treatment for refractory type I pityriasis rubra pilaris. *J Dermatol Case Rep*. 2013;7(1):5-9.
- Eytan O, Sarig O, Sprecher E, van Steensel MA. Clinical response to ustekinumab in familial pityriasis rubra pilaris caused by a novel mutation in CARD14. *Br J Dermatol*. 2014;171(2):420-422.
- Ruiz Villaverde R, Sánchez Cano D. Successful treatment of type I pityriasis rubra pilaris with ustekinumab therapy. *Eur J Dermatol*. 2010;20(5):630-631.
- Wohlrab J, Kreft B. Treatment of pityriasis rubra pilaris with ustekinumab. *Br J Dermatol*. 2010;163(3):655-656.
- Petrof G, Almaani N, Archer CB, Griffiths WA, Smith CH. A systematic review of the literature on the treatment of pityriasis rubra pilaris type 1 with TNF-antagonists. *J Eur Acad Dermatol Venereol*. 2013;27(1):e131-e135.
- Li Q, Jin Chung H, Ross N, et al. Analysis of CARD14 polymorphisms in pityriasis rubra pilaris: activation of NF-κB. *J Invest Dermatol*. 2015;135(7):1905-1908.