

PRP Patient Registry Application

Name: William McCue

DOB: 05/20/46

Current age: 71

Gender: Male

PRP Onset Date: August 8, 2012

PRP Onset Age: 66

PRP Onset Symptom(s): dime-size red spot on right temple

Differential diagnosis (early September): seborrheic dermatitis

* Christine Brown, MD, Dallas, TX

PRP diagnosis: 11/28/12

* Michael Golden, MD, Plano, TX

Treating dermatologist

* Arturo Dominguez, MD, UT Southwestern

Initial Treatment Plan:

* Acitretin (25mg to 50mg)

* Triamcinolone (body)

* Desonide (face/ears)

* Clobetasol (palms and soles)

* Hydroxyzine (itch relief)

Outcome

* Declared in remission: 04/08/2014

* Duration: 20 months

Biopsy history:

* 4 biopsies. First three were inconclusive. Fourth biopsy supported PRP.

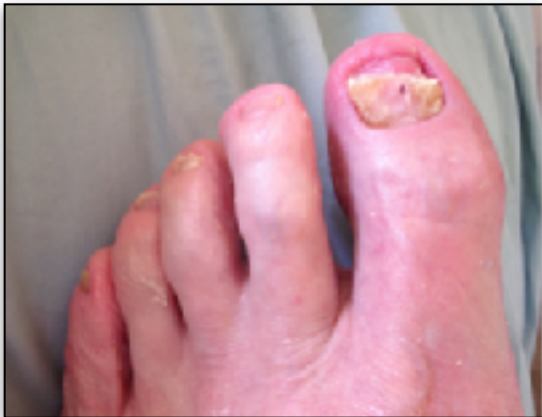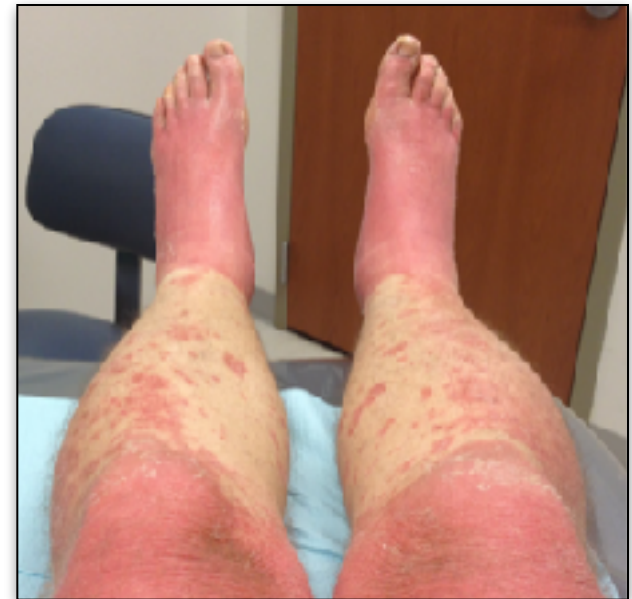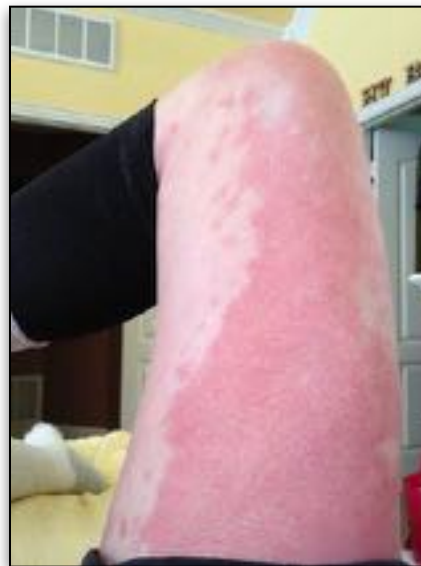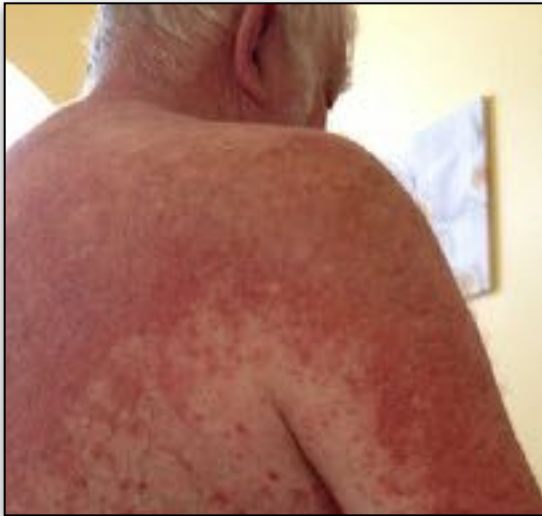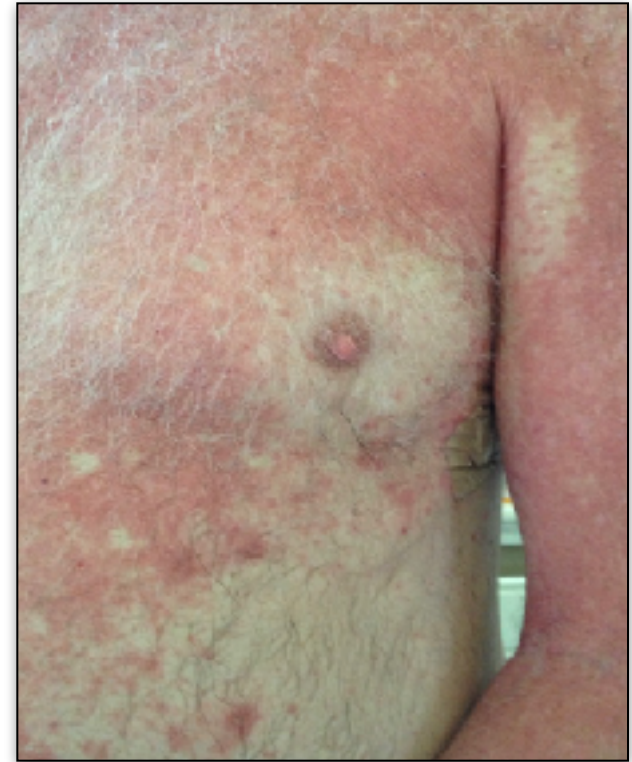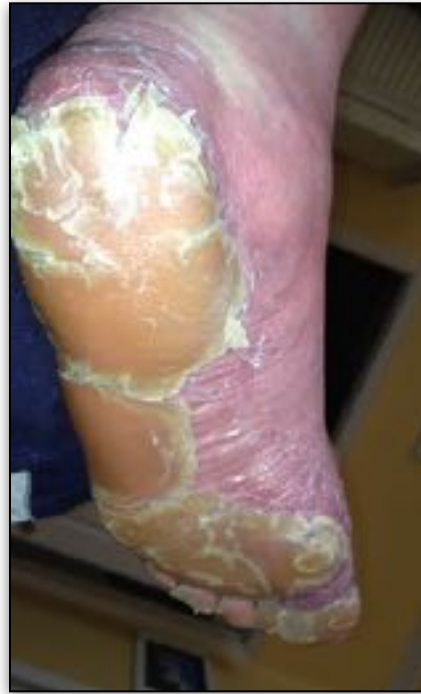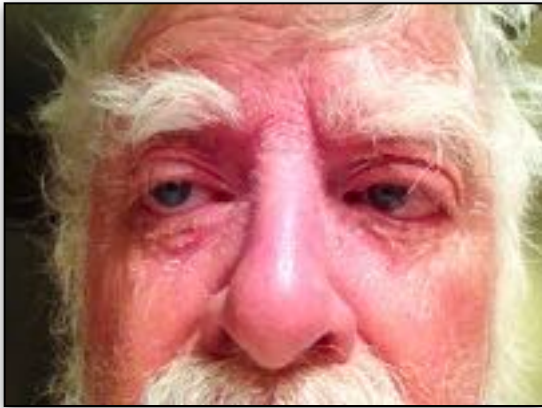
Familial history: None

Genetic Testing: Yes. Thomas Jefferson University (no results yet)



William McCue

05/20/46



William McCue

05/20/46

